

# GUIDED REVIEW PROCESS: GENERAL COMMENTS

Wilfred CG Peh

Singapore Medical Journal,  
National University of Singapore,  
Khoo Teck Puat Hospital, Singapore

# LECTURE OUTLINE

- Introduction
- General comments
  - Reviewer's summary
  - Major strengths
  - Major weaknesses
- Summary

# INTRODUCTION

- Structured review helps
  - reviewer organise thoughts in a logical manner
  - makes it easier for the editor to understand the manuscript better

# INTRODUCTION

- Structured review helps
  - Allows the authors to appreciate the major points regarding the submitted manuscript and to address concerns raised in a point-by-point manner

# INTRODUCTION

- Structured review: components
  - General comments
    - Reviewer's summary
    - Major strengths
    - Major weaknesses
    - Other general comments
  - Specific comments

## MR imaging of the humeral trochlear epiphysis: normal developmental changes during ossification

### General comments

The authors retrospectively reviewed the MR images of the elbows of 61 pediatric patients with the aim of studying the epiphyseal signal appearances. They classified MR signal characteristics into three types and concluded that there were predictable development-related changes in the trochlea on MR imaging.

This is a useful study that represents original work. The authors have convincingly shown that there are three patterns of MR imaging signal characteristics in the trochlear epiphysis of children which are likely to represent cartilaginous immature epiphysis, pre-ossification center and secondary ossification center, respectively.

The authors also acknowledge that their study suffers from several limitations. The primary ones being its retrospective nature, lack of a uniform MR imaging protocol, small cohort of patients further subdivided into three subgroups and a rather heterogeneous group of symptomatic patients referred for various indications. There is also no follow-up in the majority of patients and of course no solid proof of the authors' findings.

Bearing these limitations in mind, the authors' conclusions are probably too assertive, particularly as these have only studied a small area- the trochlear epiphysis. The general tone of their discussion and conclusions can be moderated. This study is, at best, a preliminary pilot study. The manuscript as a whole, including the abstract, should reflect this.

As an example, the purpose of the study was "to determine the changing characteristics of the humeral trochlear epiphysis.....". How can this be done on "snapshot" MR images that were retrospectively analysed at one point of time?

The illustrations chosen can also be improved to better support their findings.

### Specific comments

#### Advances in knowledge:

1. This statement is too assertive. Suggest "The MR appearance of the humeral trochlear epiphyseal cartilage appears to have three patterns of signal changes in children under 12 years of age. These reflect normal changes in the process of ossification".

2. Statement is okay.
3. This is already known and does not represent an advance in knowledge. Suggest delete this statement.

#### Implications for patient care:

1. Statement is fair.
2. Delete this statement as other epiphyses were not studied.

#### Summary statement

Too assertive. Suggest add qualifiers "may" or "probably" or "appear to", as results and conclusions in this study are based on retrospective analysis of a small group of symptomatic patients.

#### Materials and methods:

The group of patients that were selected retrospectively are a heterogeneous lot. It will be good to list the indications for imaging and numbers of patients for each indication. It appears that some of the patients that were casted were imaged with the elbow in non-standard positions. I believe that some of the indications e.g. trauma, infection, can have an effect on the MR imaging appearances of the trochlear epiphysis.

The exact type of coil used for elbow imaging should be stated.

#### Results

There is a huge standard deviation of ages in patients with type 1 and type 2 trochleas (Table 1, figure 5). Correlation of types 1 and 2 trochleas with age will be of no practical use, based on the findings of this study.

#### Discussion:

It seems only three patients underwent repeated MR imaging (not very clear exactly how many), but there appears to be too much emphasis on what is essentially anecdotal findings.

# MANUSCRIPT REVIEWING

Start by:

- Initial scanning
  - author conforms to general journal requirements and style
  - know instructions to authors
  - try to get feel and understanding of author's message

# MANUSCRIPT REVIEWING

Followed by:

- Several re-reads
- Summary of paper
- Analysis
  - major strengths & weaknesses
  - general & specific comments



# GENERAL COMMENTS

## Reviewer's summary

- Useful to the editor
  - especially - general medical journal
- Helps the reviewer distil the essence of the manuscript into a single paragraph

# MR imaging of the humeral trochlear epiphysis: normal developmental changes during ossification

## General comments

The authors retrospectively reviewed the MR images of the elbows of 61 pediatric patients with the aim of studying the epiphyseal signal appearances. They classified MR signal characteristics into three types and concluded that there were predictable development-related changes in the trochlea on MR imaging.

This is a useful study that represents original work. The authors have convincingly shown that there are three patterns of MR imaging signal characteristics in the trochlear epiphysis of children which are likely to represent cartilaginous immature epiphysis, pre-ossification center and secondary ossification center, respectively.

The authors also acknowledge that their study suffers from several limitations. The primary ones being its retrospective nature, lack of a uniform MR imaging protocol, small cohort of patients further subdivided into three subgroups and a rather heterogeneous group of symptomatic patients referred for various indications. There is also no follow-up in the majority of patients and of course no solid proof of the authors' findings.

## Reviewer's summary

# GENERAL COMMENTS

## Major strengths

- Strengths- usually list 3 major e.g. importance of findings, topic of current interest, sound methodology, control for bias, appropriate subject population, appropriate statistical analysis, practical value, innovative technique or procedure

## General comments

The authors retrospectively reviewed the MR images of the elbows of 61 pediatric patients with the aim of studying the epiphyseal signal appearances. They classified MR signal characteristics into three types and concluded that there were predictable development-related changes in the trochlea on MR imaging.

This is a useful study that represents original work. The authors have convincingly shown that there are three patterns of MR imaging signal characteristics in the trochlear epiphysis of children which are likely to represent cartilaginous immature epiphysis, pre-ossification center and secondary ossification center, respectively.

The authors also acknowledge that their study suffers from several limitations. The primary ones being its retrospective nature, lack of a uniform MR imaging protocol, small cohort of patients further subdivided into three subgroups and a rather heterogeneous group of symptomatic patients referred for various indications. There is also no follow-up in the majority of patients and of course no solid proof of the authors' findings.

## Major strengths

# GENERAL COMMENTS

## Major weaknesses

- Weaknesses- usually list 3 major e.g. no or minimal importance, flawed methodology, biased subject selection, insufficient subjects, missing inclusion and/or exclusion criteria, wrong statistical methods, data do not support conclusions

## General comments

The authors retrospectively reviewed the MR images of the elbows of 61 pediatric patients with the aim of studying the epiphyseal signal appearances. They classified MR signal characteristics into three types and concluded that there were predictable development-related changes in the trochlea on MR imaging.

This is a useful study that represents original work. The authors have convincingly shown that there are three patterns of MR imaging signal characteristics in the trochlear epiphysis of children which are likely to represent cartilaginous immature epiphysis, pre-ossification center and secondary ossification center, respectively.

The authors also acknowledge that their study suffers from several limitations. The primary ones being its retrospective nature, lack of a uniform MR imaging protocol, small cohort of patients further subdivided into three subgroups and a rather heterogeneous group of symptomatic patients referred for various indications. There is also no follow-up in the majority of patients and of course no solid proof of the authors' findings.

## Major weaknesses

# GENERAL COMMENTS

## Other comments

- Any true advance in knowledge?
  - if so, are they important and do they have a clinical application?
- Is the manuscript generally readable? Is the message clear?

heterogeneous group of symptomatic patients referred for various indications. There is also no follow-up in the majority of patients and of course no solid proof of the authors' findings.

Bearing these limitations in mind, the authors' conclusions are probably too assertive, particularly as these have only studied a small area- the trochlear epiphysis. The general tone of their discussion and conclusions can be moderated. This study is, at best, a preliminary pilot study. The manuscript as a whole, including the abstract, should reflect this.

As an example, the purpose of the study was "to determine the changing characteristics of the humeral trochlear epiphysis.....". How can this be done on "snapshot" MR images that were retrospectively analysed at one point of time?

The illustrations chosen can also be improved to better support their findings.

## Specific comments

## Other general comments



# GENERAL COMMENTS

## Other comments

- Is the manuscript appropriate for readership?
- Is there any other paper that is substantially similar?
  - duplicate publication/ plagiarism

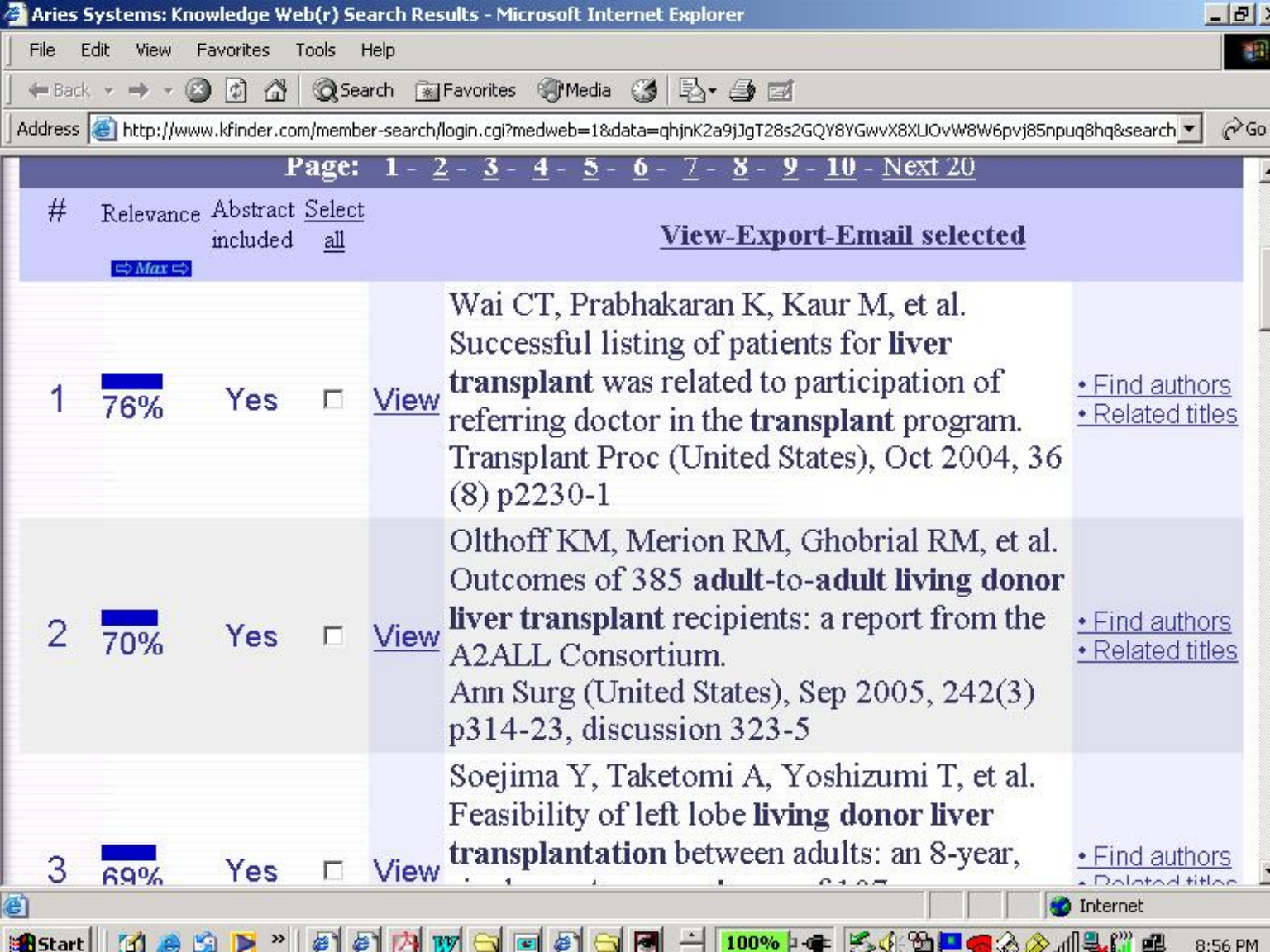
# SMJ SINGAPORE MEDICAL JOURNAL

HOME • LOG OUT • HELP • REGISTER • UPDATE MY INFORMATION • JOURNAL OVERVIEW  
 MAIN MENU • CONTACT US • SUBMIT A MANUSCRIPT • INSTRUCTIONS FOR AUTHORS

Username: wcgpeh

Role: Editor-in-


<a href="#">View Submission</a> <a href="#">Details</a> <a href="#">History</a> <a href="#">Download Files</a> <a href="#">Classifications</a> <a href="#">Assign Editor</a> <a href="#">Invite Reviewers</a> <a href="#">Solicit Commentary</a> <a href="#">Similar Articles in MEDLINE</a>	SMJ-2006- 	Original Article	Daily enteral and parenteral nutrition in head trauma patients on the ICU		Jul 0 200
<a href="#">View Submission</a> <a href="#">Details</a> <a href="#">History</a> <a href="#">Download Files</a> <a href="#">Classifications</a> <a href="#">Assign Editor</a> <a href="#">Invite Reviewers</a> <a href="#">Solicit Commentary</a> <a href="#">Similar Articles in MEDLINE</a>	SMJ-2006- 	Case Report	Lichen amyloidosis in an unusual location		Jul 0 200



Page: 1 - 2 - 3 - 4 - 5 - 6 - 7 - 8 - 9 - 10 - Next 20

# Relevance Abstract included Select all

[View-Export-Email selected](#)

1  76% Yes

[View](#) Wai CT, Prabhakaran K, Kaur M, et al. Successful listing of patients for **liver transplant** was related to participation of referring doctor in the **transplant** program. Transplant Proc (United States), Oct 2004, 36 (8) p2230-1

[Find authors](#)  
[Related titles](#)

2  70% Yes

[View](#) Olthoff KM, Merion RM, Ghobrial RM, et al. Outcomes of 385 **adult-to-adult living donor liver transplant** recipients: a report from the A2ALL Consortium. Ann Surg (United States), Sep 2005, 242(3) p314-23, discussion 323-5

[Find authors](#)  
[Related titles](#)

3  69% Yes

[View](#) Soejima Y, Taketomi A, Yoshizumi T, et al. Feasibility of left lobe **living donor liver transplantation** between adults: an 8-year,

[Find authors](#)  
[Related titles](#)

## COMPARISON OF QUALITATIVE AND QUANTITATIVE EVALUATION OF DIFFUSION-WEIGHTED MRI AND CHEMICAL-SHIFT IMAGING IN THE DIFFERENTIATION OF BENIGN AND MALIGNANT VERTEBRAL BODY FRACTURES.

### General comments

The authors prospectively compared qualitative diffusion-weighted imaging (DWI), quantitative DWI and chemical shift imaging in 26 patients with osteoporotic vertebral fractures and 20 patients with malignant vertebral fractures. They found that DW-PSIF (delta 3ms) had the highest accuracy in differentiating benign from malignant fractures, with quantitative chemical shift imaging and quantitative DW-ss TSE being less accurate. They concluded that quantitatively assessed opposed-phase, DW-EPI and DW-ss TSE and quantitative DW-EPI were not suitable to differentiate between benign and malignant vertebral fractures.

The MRI techniques are generally well described and the results are generally convincing. The conclusions appear valid.

However, this study suffers from having a relatively small study cohort. This raises some questions about the study power and validity of conclusions drawn. Only 24 out of 46 patients had histological proof of diagnosis; while the other determinants of diagnosis (follow-up MRI, PET-CT and clinical follow-up) are not unreasonable, this reduces the confidence in the results and conclusions. The degree of sclerosis/calcification and tumor characteristics in the vertebral body assessed may impact on the MRI signal changes.

Some minor grammatical and typo errors require editing.

**"Atypical Pattern of Bone Marrow Edema in the Medial Femoral Condyle of Military Recruits. Is it Related to Repetitive Self Induced Trauma?."**

## General Comments

### Summary

A retrospective study of bone marrow edema in 9 military recruits in the extraarticular medial aspect of the medial femoral condyle related to repetitive self induced trauma. It is a curious etiology of bone marrow edema not previously published. It is Interesting but of questionable practical value to readers of Radiology.

### Major strengths

- Curious etiology of bone marrow edema (self induced trauma) not previously published.
- The article is well written.
- Figures of very good quality and demonstratives.

### Major weaknesses

- Small group of patients.
- Absence of a control group of patients.

# SUMMARY

- Reviews are ideally structured
  - helpful to reviewers, editors and authors
- General comments
  - reviewer's summary
  - major strengths and weaknesses
  - other general comments